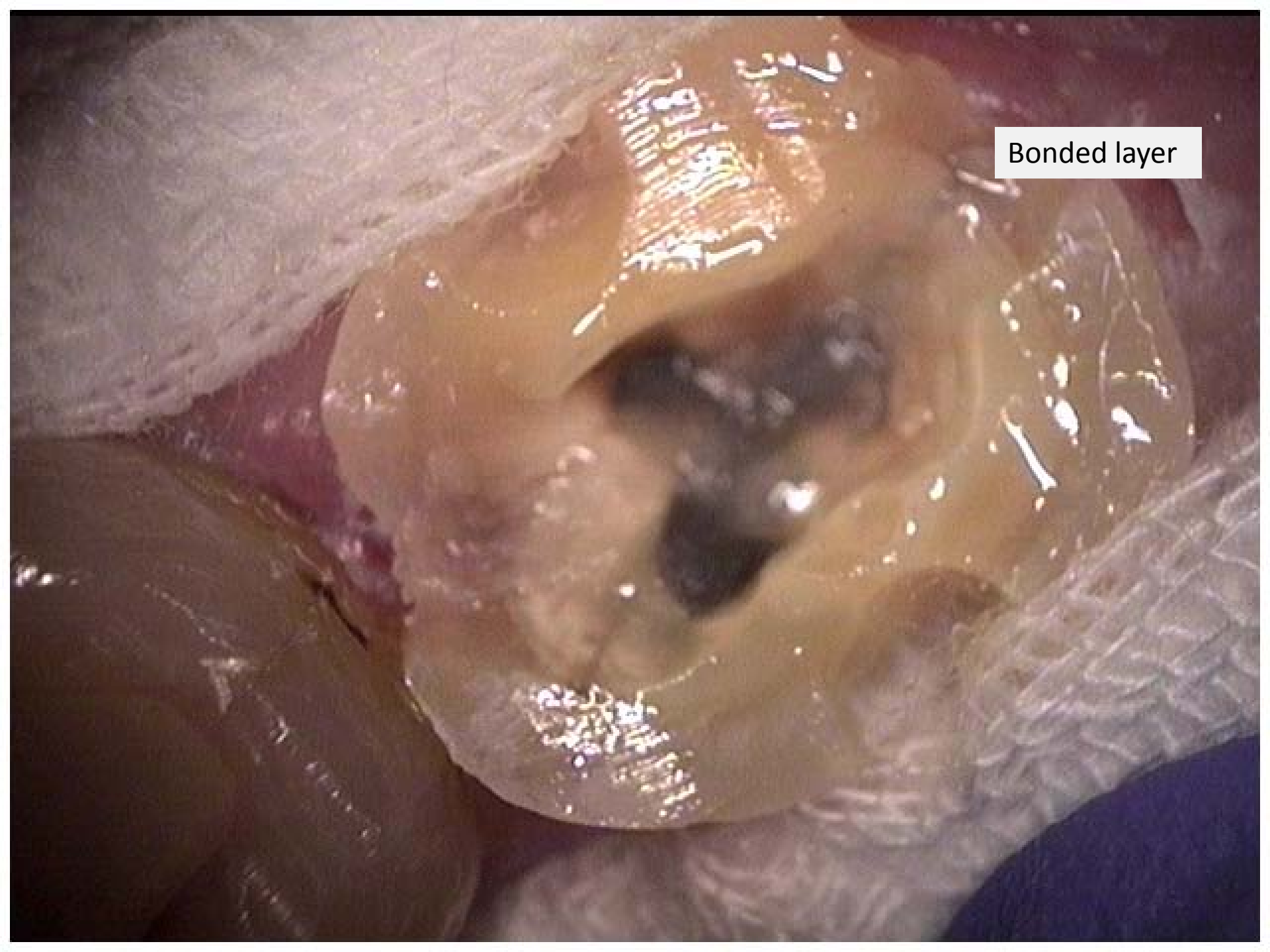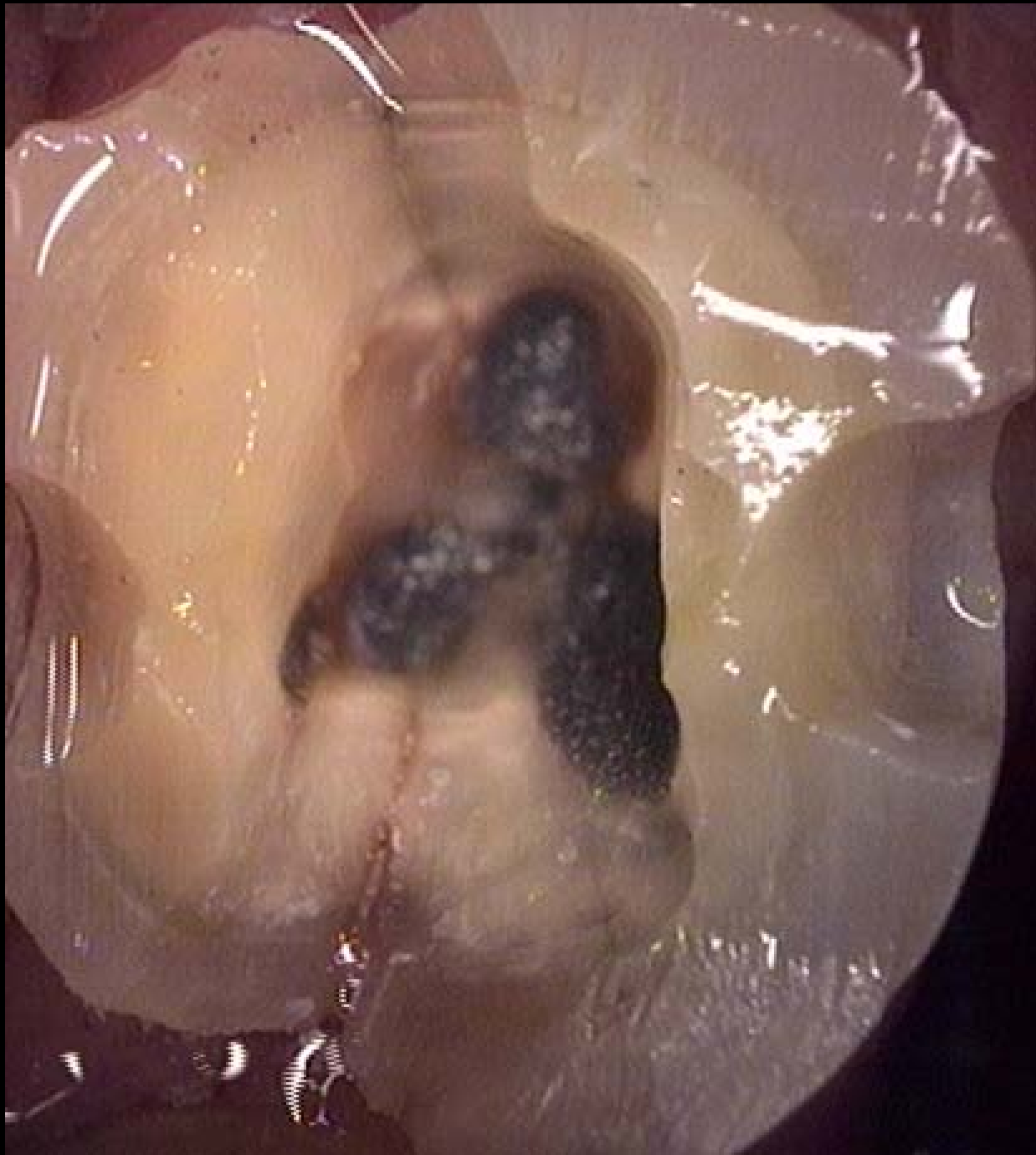
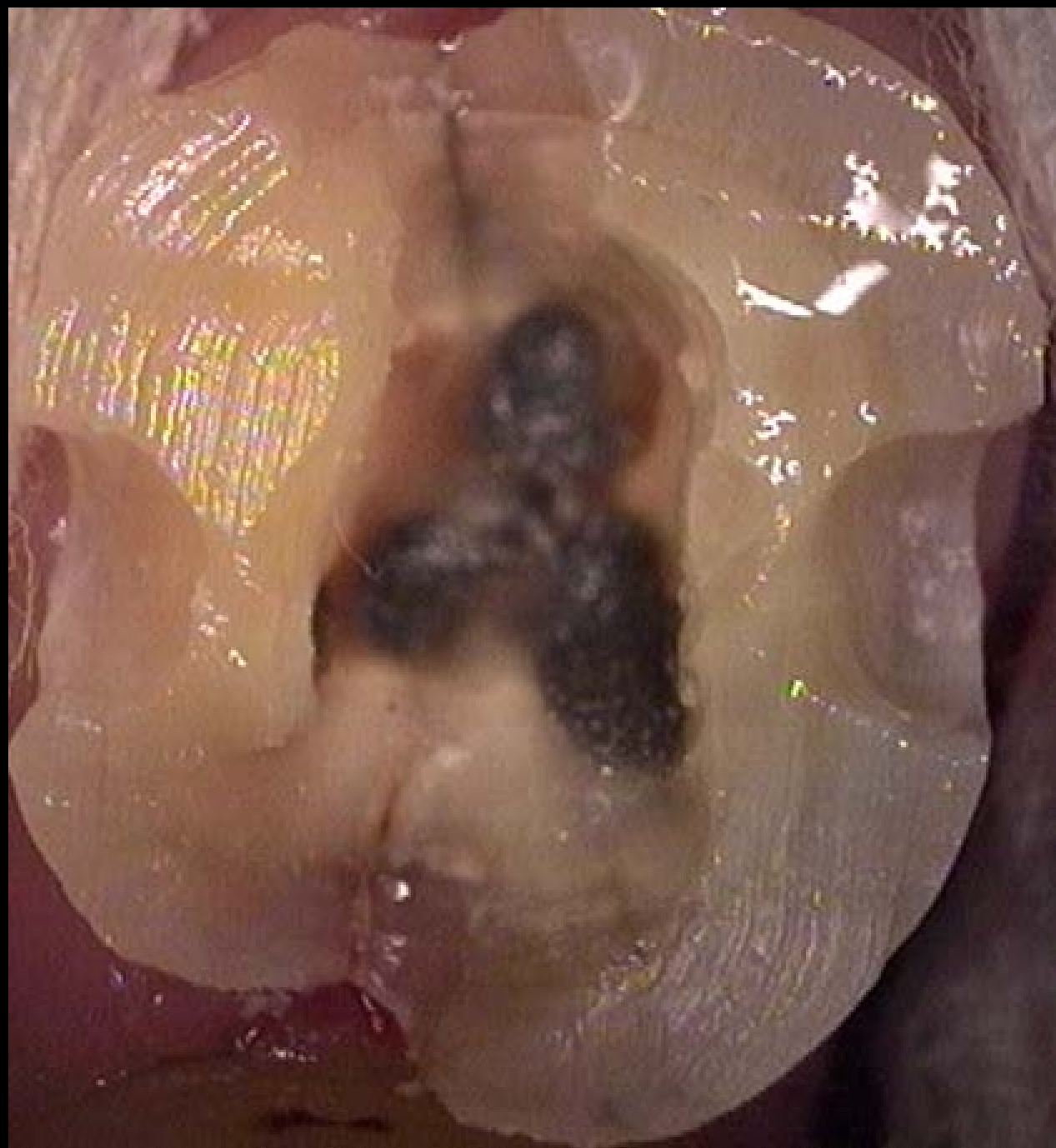



Endodontics done a year prior. Patient did not follow-up with crown. No symptoms presented.

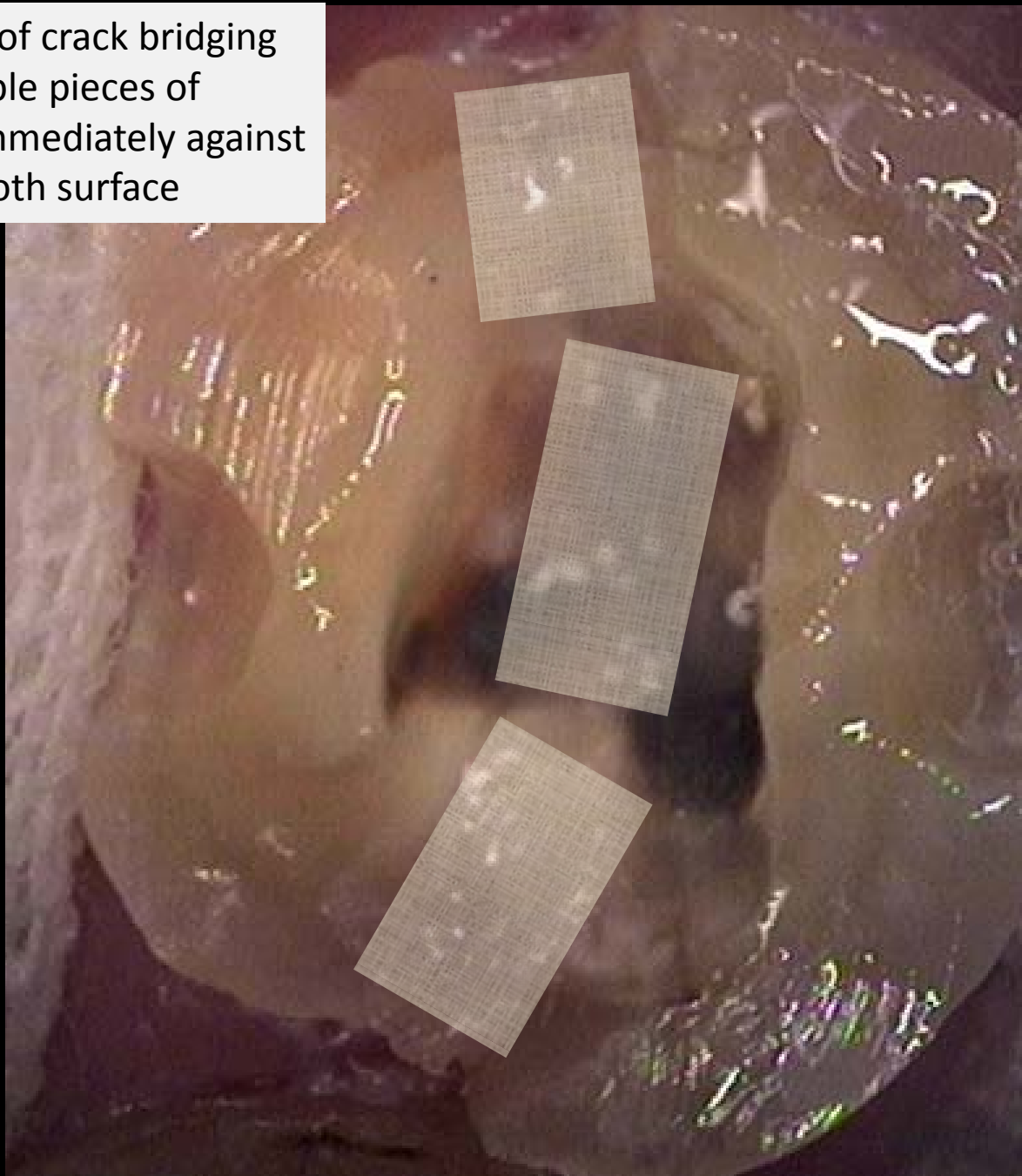
*Case and photos courtesy of Dr. John Derango*



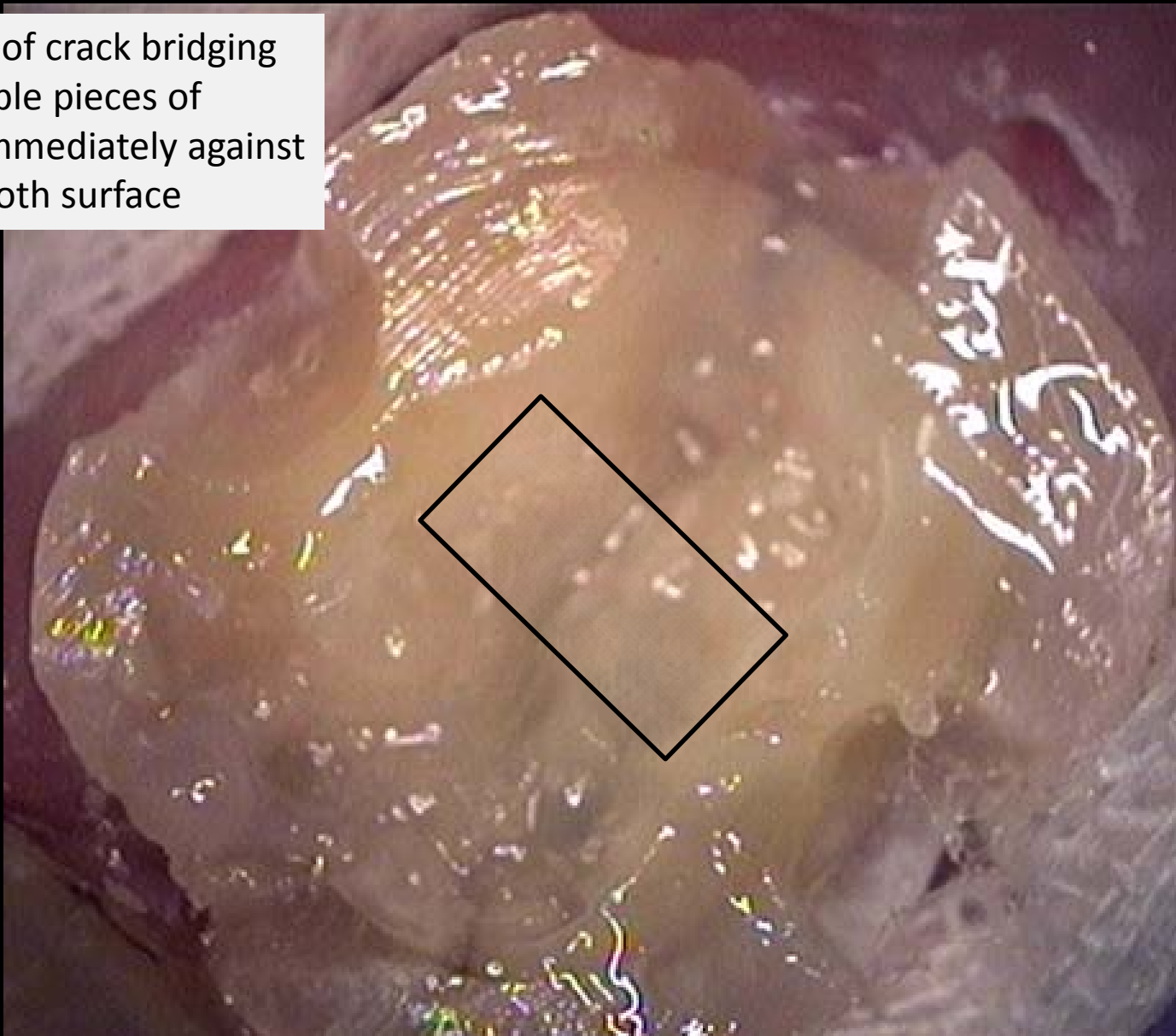
A close-up photograph of a dental procedure. A tooth is being prepared with a bonding agent. The bonding agent is a thick, translucent, yellowish-brown material that is being applied to the tooth's surface. The tooth is held in place by a white gauze pad. The background is dark, and the lighting is focused on the tooth and the bonding agent. A white box with the text "Bonded layer" is overlaid on the image.

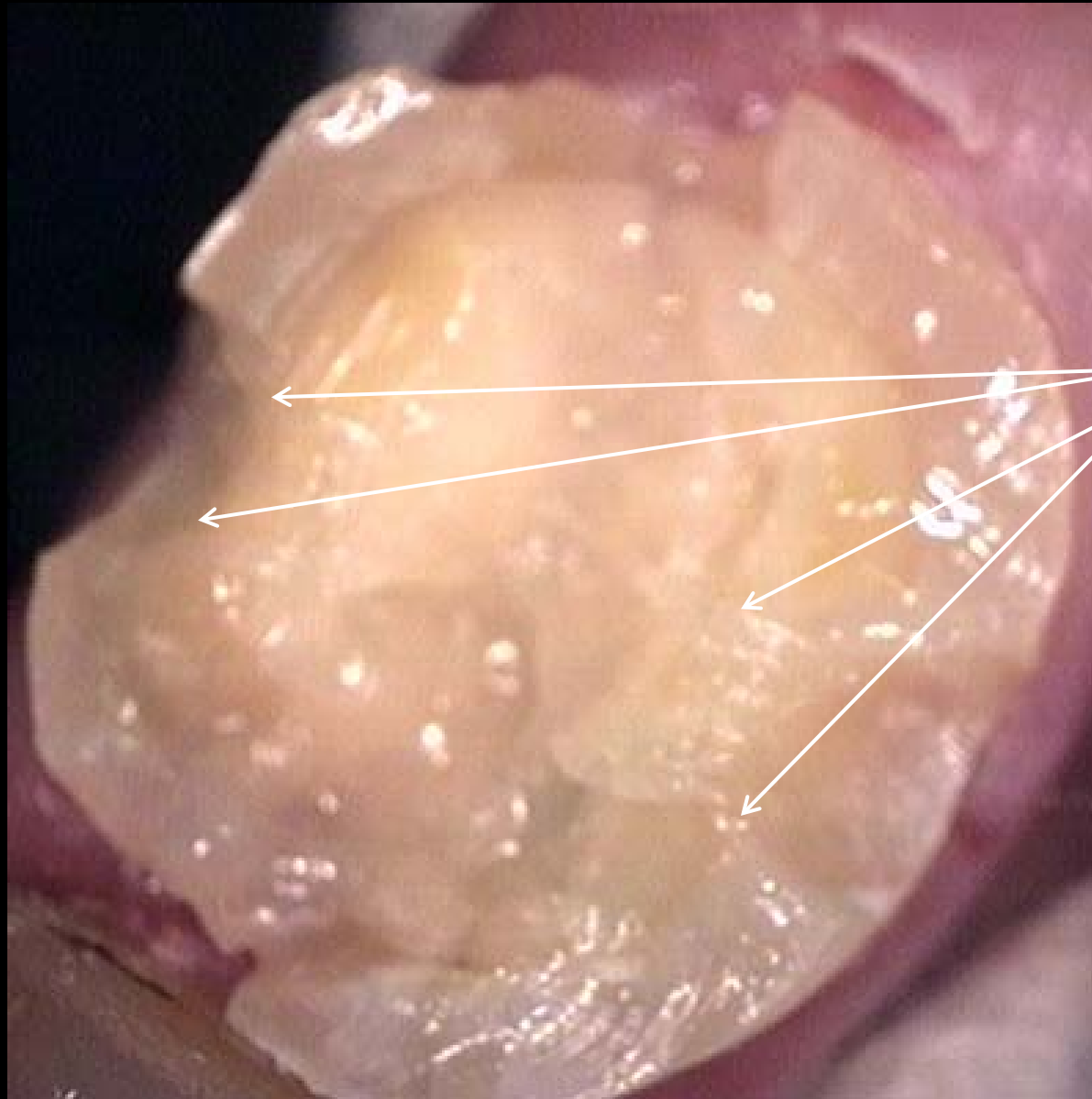
Bonded layer

Schematic of crack bridging  
with multiple pieces of  
Ribbond immediately against  
bonded tooth surface

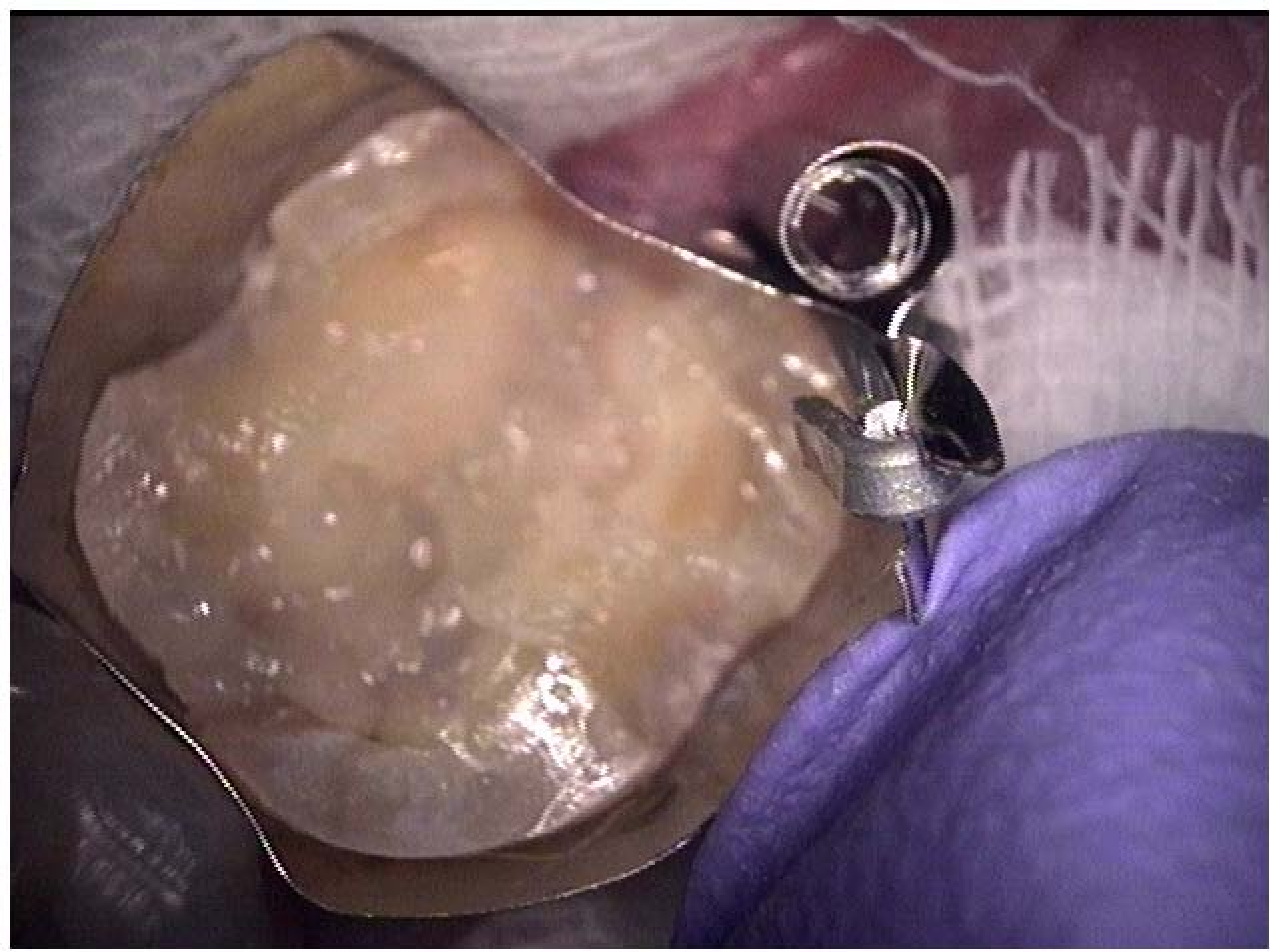

Schematic of crack bridging  
with multiple pieces of  
Ribbond immediately against  
bonded tooth surface





1 piece of fiber from buccal to lingual through grooves. This creates a greater global crack bridging effect on the entire tooth.



To prepare for long term provisional later, composite is placed over the top.

