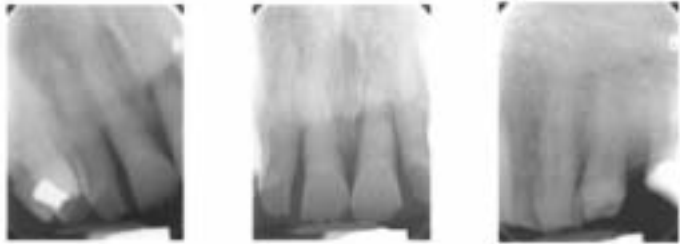
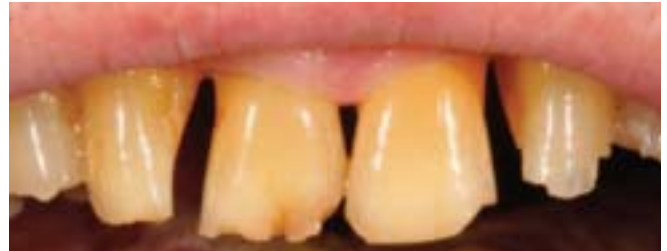
“A case that was accomplished using Ribbond to splint periodontally involved teeth that were then built-up with composite resin for esthetic and functional enhancement. The patient was then referred to the periodontist for evaluation and treatment. The splinting allowed for a more stable periodontal situation if surgery is warranted, and the esthetic advantage of the Ribbond became evident in the frontal view. We have found Ribbond to be an excellent splint material for periodontal and orthodontic splints, the fact that it works so well in these transitional bonding cases is just another arrow in the quiver for Ribbond.”

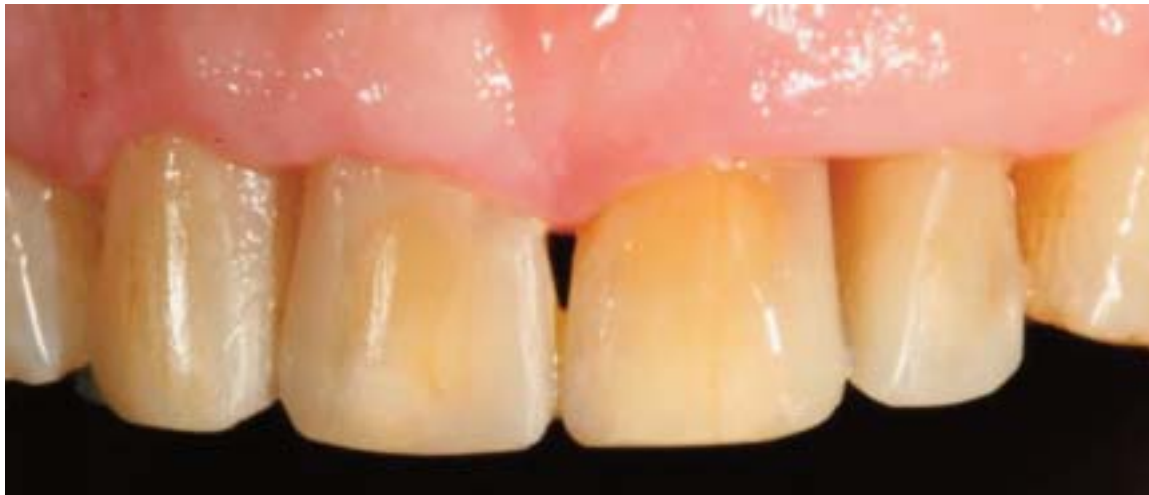
*Case and photos courtesy of:  
Arthur R. Volker DDS*



Pre-Treatment Film



Pre-Treatment Presentation



Post-Treatment Presentation